

GUIDELINES ON PAEDIATRIC UROLOGY

(Text update March 2013)

S. Tekgül (co-chair), H. Riedmiller (co-chair), H.S. Dogan,
P. Hoebeke, R. Kocvara, J.M. Nijman (vice-chair),
Chr. Radmayr, R. Stein

Introduction

Due to the scope of the extended Guidelines on Paediatric Urology, no attempt has been made to include all topics, but rather to provide a selection based on practical considerations.

PHIMOSIS **Background**

At the end of the first year of life, retraction of the foreskin behind the glanular sulcus is possible in only about 50% of boys. The phimosis is either primary (physiological), with no sign of scarring, or secondary (pathological), resulting from scarring due to conditions such as balanitis xerotica obliterans.

Phimosis must be distinguished from normal agglutination of the foreskin to the glans, which is a physiological phenomenon. If the tip remains narrow and glanular adhesions are separated, then the space is filled with urine during voiding, causing the foreskin to balloon outward.

Treatment

Plastic circumcision (dorsal incision, partial circumcision) carries the potential for recurrence of the phimosis. Associated frenulum breve is corrected by frenulotomy. Meatoplasty is added if necessary. Childhood circumcision should not be recommended without a medical reason.

Circumcision: indication and contraindication

Contraindications for circumcision are coagulopathy, an acute local infection and congenital anomalies of the penis, particularly hypospadias or buried penis, because the foreskin may be required for a reconstructive procedure.

Conservative treatment

Agglutination of the foreskin does not respond to steroid treatment.

Paraphimosis

It is characterised by retracted foreskin with the constrictive ring localised at the level of the sulcus. A dorsal incision of the constrictive ring may be required, or circumcision is carried out immediately or in a second session.

CRYPTORCHIDISM

Clinical management is determined by classification into palpable and non-palpable testes.

Diagnosis

Physical examination is the only method of differentiating palpable and non-palpable testes. There is no benefit from ultrasonography (US), computed tomography (CT), magnetic resonance imaging (MRI) or CT angiography (CTA).

Surgical treatment

Surgery differs for palpable or non-palpable testes.

Orchidopexy (inguinal approach) is used for palpable testis (up to 92% success). Inguinal surgical exploration should be attempted for non-palpable testes. Laparoscopy can be used for testis removal or orchidolysis and orchiopexy.

Prognosis

Boys with one undescended testis have a lower fertility rate, but the same paternity rate as boys with bilateral descended testes. Boys with an undescended testis are 20 times more likely to develop testicular malignancy, independent of treatment choice.

Recommendations for cryptorchidism	LE	GR
Boys with retractile testes do not need medical or surgical treatment, but require close follow-up until puberty.	2	A
Surgical orchidolysis and orchidopexy should be concluded at the age of 12 months, or 18 months the latest.	3	B
In case of non-palpable testes and no evidence of disorders of sex development, laparoscopy still represents the gold standard because it has almost 100% sensitivity and specificity in identifying an intraabdominal testis as well as the possibility for subsequent treatment in the same session.	1b	A
Hormonal therapy, either in an adjuvant or neo-adjuvant setting, is not standard treatment. Patients have to be evaluated on an individual basis.	2	C
For an intra-abdominal testis in a 10-year-old boy or older, with a normal contralateral testis, removal is an option because of the theoretical risk of a later malignancy.	3	B

HYDROCELE

Background

Incomplete obliteration of the processus vaginalis peritonei results in formation of various types of communicating hydrocele, alone or connected with other intrascrotal pathology (hernia).

Non-communicating hydroceles are found secondary to minor trauma, testicular torsion, epididymitis, or varicocele operation, or may appear as a recurrence after primary repair of a communicating hydrocele.

A *communicating hydrocele* vacillates in size, usually relative to activity. It is diagnosed by medical history and physical investigation, the swelling is translucent, and transillumination of the scrotum makes the diagnosis. If there are any doubts about the intrascrotal mass, US should be performed. Contralateral disease should be excluded.

Surgical treatment

Surgical treatment of hydrocele is not indicated within the first 12-24 months because of the tendency for spontaneous resolution.

Early surgery is indicated if there is suspicion of a concomitant inguinal hernia or underlying testicular pathology. There is no evidence that this type of hydrocele risks testicular damage.

In the paediatric age group, the operation consists of ligation of the patent processus vaginalis via an inguinal incision, leaving the distal stump open, whereas in hydrocele of the cord, the cystic mass is excised or unroofed. Sclerosing agents should not be used because of the risk of chemical peritonitis in the communicating processus vaginalis peritonei.

The scrotal approach (Lord or Jaboulay technique) is used in the treatment of a secondary non-communicating hydrocele.

HYPOSPADIAS

Background

Hypospadias are usually classified according to the anatomical location of the proximally displaced urethral orifice:

- distal - anterior hypospadias (glanular, coronal or distal penile);
- intermediate - middle (penile);
- proximal - posterior (penoscrotal, scrotal, perineal).

The pathology may be much more severe after skin release.

Assessment

Patients with hypospadias should be diagnosed at birth. The diagnostic evaluation also includes an assessment of associated anomalies, which are cryptorchidism and open processus vaginalis or inguinal hernia. Severe hypospadias with unilaterally or bilaterally impalpable testis, or with ambiguous genitalia, require a complete genetic and endocrine work-up immediately after birth to exclude intersexuality, especially congenital adrenal hyperplasia.

Trickling urine and ballooning of the urethra require exclusion of meatal stenosis.

The length of the hypospadiac penis may be distorted by penile curvature, by penoscrotal transposition, or may be smaller due to hypogonadism.

Differentiation between functionally necessary and aesthetically feasible operative procedures is important for therapeutic decision-making. As all surgical procedures carry the risk of complications, thorough pre-operative counselling of the parents is crucial. The therapeutic objectives are to correct

the penile curvature, to form a neo-urethra of an adequate size, to bring the neomeatus to the tip of the glans, if possible, and to achieve an overall acceptable cosmetic appearance. This goal is achieved by using different surgical techniques according to the individual findings.

Surgery

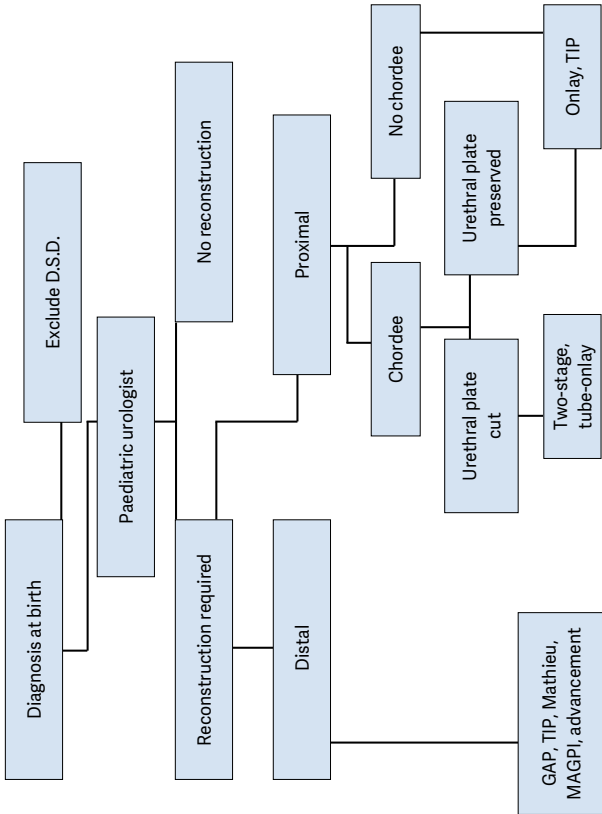
For repeat hypospadias repairs, no definitive guidelines can be given.

Outcome

Excellent long-term functional and cosmetic results can be achieved after repair of anterior penile hypospadias. The complication rate in proximal hypospadias repair is higher.

Fig. 1 gives an algorithm for the management of hypospadias.

Fig. 1: Algorithm for the management of hypospadias



D.S.D. = disorders of sexual differentiation; GAP = glans approximation procedure; TIP = tubularized incised plate urethroplasty; MAGPI = meatal advancement and glanuloplasty incorporated.

MICROPENIS

Micropenis is defined as a small but otherwise normally formed penis with a stretched length of less than $2.5 \text{ cm} \pm \text{SD}$ below the mean (Table 1).

Age	Mean \pm SD (cm)
Newborns	3.5 ± 0.4
0-5 months	3.9 ± 0.8
6-12 months	4.3 ± 0.8
1-2 y	4.7 ± 0.8
2-3 y	5.1 ± 0.9
3-4 y	5.5 ± 0.9
4-5 y	5.7 ± 0.9
5-6 y	6.0 ± 0.9
6-7 y	6.1 ± 0.9
7-8 y	6.2 ± 1.0
8-9 y	6.3 ± 1.0
9-10 y	6.3 ± 1.0
10-11 y	6.4 ± 1.1
Adults	13.3 ± 1.6

VARICOCELE IN CHILDREN AND ADOLESCENTS

Background

Varicocele is unusual in boys under 10 years of age, but becomes more frequent at the beginning of puberty. Fertility problems will arise in about 20% of adolescents with varicocele. The adverse influence of varicocele increases with time.

Testicular catch-up growth and improvement in sperm para-

meters after varicocelectomy has been reported in adolescents.

Varicocele is mostly asymptomatic, rarely causing pain at this age. It may be noticed by the patient or parents, or discovered by the paediatrician at a routine visit. Diagnosis and classification depends upon the clinical finding and ultrasound investigation.

Surgical treatment

Surgical intervention is based on ligation or occlusion of the internal spermatic veins. Microsurgical lymphatic-sparing repair (microscopic or laparoscopic) are associated with the lowest recurrence and complication rates. There is no evidence that treatment of varicocele at paediatric age will offer a better andrological outcome than an operation performed later.

Follow-up

During adolescence, testicular size should be checked annually. After adolescence, repeated sperm analysis is to be recommended.

Fig. 2 shows an algorithm for the diagnosis of varicocele in children and adolescents, and Fig. 3 shows an algorithm for its treatment.

Fig. 2: Algorithm for the diagnosis of varicocele in children and adolescents

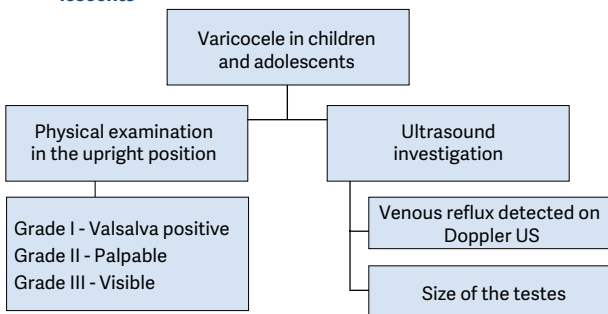
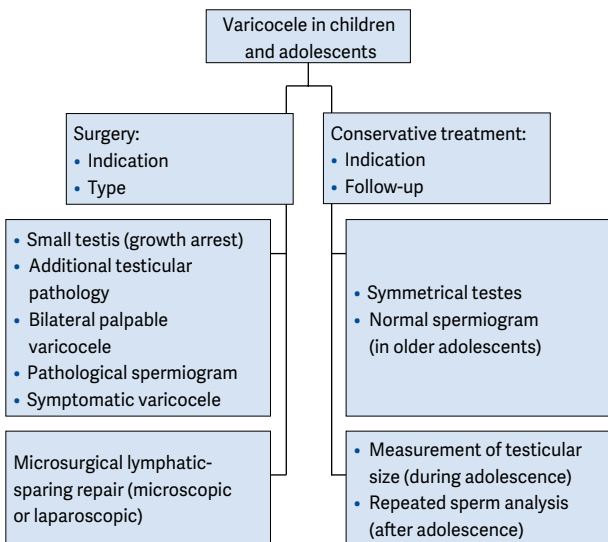


Fig. 3: Algorithm for the treatment of varicocele in children and adolescents



MONOSYMPTOMATIC NOCTURNAL ENURESIS

Background

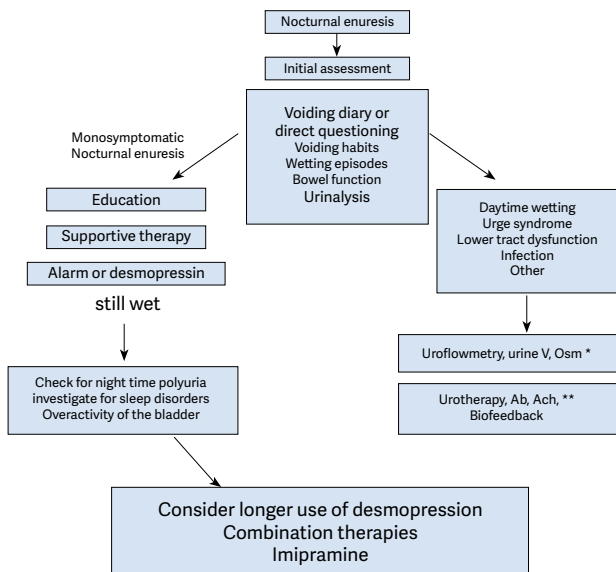
Enuresis is incontinence during the night. Any wetting during sleep above the age of five years is enuresis. It is important to note that there is a single symptom only. Due to an imbalance between night-time urine output and night-time bladder capacity, the bladder can easily become full at night, and the child will either wake up to empty the bladder or will void during sleep.

Assessment

A voiding diary, registering the daytime bladder function and the night-time urine output will help guide the treatment. Measuring the daytime bladder capacity gives an estimate of bladder capacity to compare with normal values for age.

Fig. 4 gives an algorithm for the diagnosis and treatment of monosymptomatic nocturnal enuresis.

Fig. 4: Algorithm for the diagnosis and treatment of monosymptomatic nocturnal enuresis



Vesicoureteric Reflux (VUR) in children

VUR present within a wide range of severity, and a majority of reflux patients will not develop renal scars and probably will not need any intervention. The main goal in management is the preservation of kidney function.

Diagnosis

The diagnostic work-up should evaluate the overall health and development of the child. A basic diagnostic work-up includes a detailed medical history (including family history, and screening for lower urinary tract dysfunction [LUTD]), physical examination including blood pressure measurement, urinaly-

sis (assessing proteinuria), urine culture, and serum creatinine in patients with bilateral renal parenchymal abnormalities.

Prenatally diagnosed hydronephrosis

Ultrasound of the kidney and bladder is the first standard evaluation tool for children with prenatally diagnosed hydronephrosis. It should be delayed to the end of first week after birth because of early oliguria in the neonate. It is essential to evaluate the bladder, as well as the kidneys.

Recommendations for the use of VCU in prenatal hydronephrosis
US findings of bilateral high-grade hydronephrosis, duplex kidneys, ureterocele, ureteric dilatation, and abnormal bladders, because the likelihood of VUR is much higher.
In all other conditions, the use of VCU to detect reflux is optional.
When cases identified by prenatal US become symptomatic with UTIs, further evaluation with VCU should be considered.
Recommendations for paediatric screening of VUR
The parents of children with VUR should be informed that siblings and offspring have a high prevalence of VUR.
If screening is performed, siblings should be screened by renal US. VCU is recommended if there is evidence of renal scarring on US or a history of UTI.
In older children who are toilet-trained, there is no added value in screening for VUR.

UTI = urinary tract infecting; VCU = voiding cystourethrography.

Conservative therapy

The objective of conservative therapy is prevention of febrile UTI. It is based on the understanding that:

- VUR resolves spontaneously, mostly in young patients with low-grade reflux. However, spontaneous resolution is low for bilateral high-grade reflux).
- VUR does not damage the kidney when patients are free of infection and have normal lower urinary tract function.
- There is no evidence that small scars can cause hypertension, renal insufficiency or problems during pregnancy.
- The conservative approach includes watchful waiting, intermittent or continuous antibiotic prophylaxis, and bladder rehabilitation in those with LUTD.
- Circumcision during early infancy may be considered as part of the conservative approach, because it is effective in reducing the risk of infection in normal children.

Surgical treatment

Surgical treatment comprises endoscopic injection of bulking agents or ureteral reimplantation.

Subureteric infection of bulking agents: due to the availability of biodegradable substances, endoscopic subureteric injection of bulking agents has become an alternative to long-term antibiotic prophylaxis and surgical intervention.

Open surgical techniques: Overall, all surgical procedures offer very high and similar success rates for correcting VUR.

Laparoscopy: a laparoscopic approach cannot be recommended as a routine procedure. It can be offered as an alternative to the parents in centres where there is enough experience.

Recommendations for the management of VUR in childhood

Regardless of the grade of reflux or presence of renal scars, all patients diagnosed within the first year of life should be treated initially with CAP. During early childhood, the kidneys are at higher risk of developing new scars. Immediate, parenteral antibiotic treatment should be initiated for febrile breakthrough infections. Definitive surgical or endoscopic correction is the preferred treatment in patients with frequent breakthrough infections.

Surgical correction should be considered in patients with persistent high-grade reflux (grades IV/V). There is no consensus about the timing and type of surgical correction. The outcome of open surgical correction is better than endoscopic correction for higher grades of reflux, whereas satisfactory results can be achieved by endoscopic injection for lower grades.

There is no evidence that correction of persistent low-grade reflux (grades I–III) without symptoms and normal kidneys offers a significant benefit. These patients may be candidates for endoscopic treatment.

In all children presenting at age 1–5 years, CAP is the preferred option for initial therapy. For those with high-grade reflux or abnormal renal parenchyma, surgical repair is a reasonable alternative. In patients with lower grades of reflux and without symptoms, close surveillance without antibiotic prophylaxis may be an option.

A detailed investigation for the presence of LUTD should be performed in all children after toilet-training. If LUTD is found, the initial treatment should always be for LUTD.

If parents prefer definitive therapy to conservative management, surgical correction may be considered. Endoscopic treatment is an option for all children with low grades of reflux.

The traditional approach of initial medical treatment after diagnosis and shifting to interventional treatment in case of breakthrough infections and new scar formation needs to be challenged, because the treatment should be tailored to different risk groups.

The choice of management depends on the presence of renal scars, clinical course, grade of reflux, ipsilateral renal function, bilaterality, bladder function, associated anomalies of the urinary tract, age, compliance, and parental preference. Febrile UTI, high-grade reflux, bilaterality, and cortical abnormalities are considered to be risk factors for possible renal damage. The presence of LUTD is an additional risk factor for new scars.

In high-risk patients who already have renal impairment, a more aggressive, multidisciplinary approach is needed.

CAP = continuous antibiotic prophylaxis.

Table 2: Management and follow-up according to different risk groups

Risk Groups	Presentation	Initial treatment	
High	Symptomatic male or female patients after toilet-training with high-grade reflux (grades IV/V), abnormal kidneys and LUTD	Initial treatment is always for LUTD; intervention may be considered in cases of recurrent febrile infections or persistent reflux	
High	Symptomatic male or female patients after toilet-training with high-grade reflux (grade IV/V), abnormal kidneys and no LUTD	Intervention should be considered	
Moderate	Symptomatic male or female patients before toilet-training, with high-grade reflux and abnormal kidneys	CAP is the initial treatment. Intervention may be considered in cases of breakthrough infections or persistent reflux	
Moderate	Asymptomatic patients (PNH or sibling) with high-grade reflux and abnormal kidneys	CAP is the initial treatment. Intervention may be considered in cases of breakthrough infections or persistent reflux	

		Follow-up
	Greater possibility of earlier intervention	More aggressive follow-up for UTI and LUTD; full re-evaluation after 6 months
	Open surgery has better results than endoscopic surgery	Postoperative VCU on indication only; follow-up of kidney status until after puberty
	Spontaneous resolution is higher in males	Follow-up for UTI/hydronephrosis; full re-evaluation after 12–24 months
		Follow-up for UTI/hydronephrosis; full re-evaluation after 12–24 months

Moderate	Symptomatic male or female patients after toilet-training, with high-grade reflux and normal kidneys with LUTD	Initial treatment is always for LUTD. Intervention may be considered in cases of breakthrough infections or persistent reflux	
Moderate	Symptomatic male or female patients after toilet-training with low-grade reflux, abnormal kidneys with or without LUTD	Choice of treatment is controversial. Endoscopic treatment may be an option. LUTD treatment should be given if needed.	
Moderate	All symptomatic patients with normal kidneys, with low-grade reflux, with LUTD	Initial treatment is always for LUTD	
Low	All symptomatic patients with normal kidneys, with low-grade reflux, with no LUTD	No treatment or CAP	
Low	All asymptomatic patients with normal kidneys with low-grade reflux	No treatment or CAP in infants	

PNH = prenatal diagnosed hydronephrosis.

	In case of persistent LUTD, despite urotherapy, intervention should be considered. The choice of intervention is controversial	Follow-up for UTI and LUTD, kidney status; full re-evaluation after successful urotherapy
		Follow-up for UTI, LUTD, and kidney status until after puberty
		Follow-up for UTI and LUTD
	If no treatment is given, parents should be informed about risk of infection	Follow-up for UTI
	If no treatment is given, parents should be informed about risk of infection	Follow-up for UTI

This short text is based on the more comprehensive EAU/ESPU Paediatric Urology Guidelines (ISBN 978-90-79754-71-7), available at their website, <http://www.uroweb.org>.